

Tritrichomonas foetus in cats

Dr Chris Helps and Dr Séverine Tasker

**Langford Veterinary Services
Langford House
Langford
Bristol
BS40 5DU**

Why is *Tritrichomonas foetus* infection important in cats?

Tritrichomonas foetus (TF) is a significant cause of infertility and abortion in cattle in many parts of the world, and has recently been established as a cause of disease in cats. However reproductive disease does not appear to be an important manifestation of TF infection in cats (Gray, *et al* 2010), suggesting that bovine and feline isolates are adapted to their host. Instead, this flagellated protozoal parasite is well recognised as a cause of large bowel diarrhoea in cats (Gookin, *et al* 2001, Gunn-Moore and Tennant 2007, Gunn-Moore, *et al* 2007). Around 20% of feline faecal samples submitted to a UK diagnostic laboratory for TF testing were positive for the agent (Gunn-Moore and Tennant 2007), indicating that it is a common infection in the UK.

Clinical signs of feline *Tritrichomonas foetus* infection

The parasite targets the large bowel, colonising the ileum, caecum and colon, where it can cause lymphocytic, plasmacytic inflammation and chronic diarrhoea. Clinical signs range from asymptomatic to severe intractable diarrhoea, which can be foul-smelling and is characterised by the frequent passage of small quantities of liquid to semi-formed faeces often with blood, mucus and straining. Anal irritation may also be a feature, and in severe cases cats may develop faecal incontinence. Despite the presence of severe diarrhoea, most cats do not lose weight as it is primarily the large intestine that is affected. Indeed most cats with TF infection are not systemically ill, so if this is present it is important to look for other underlying diseases.

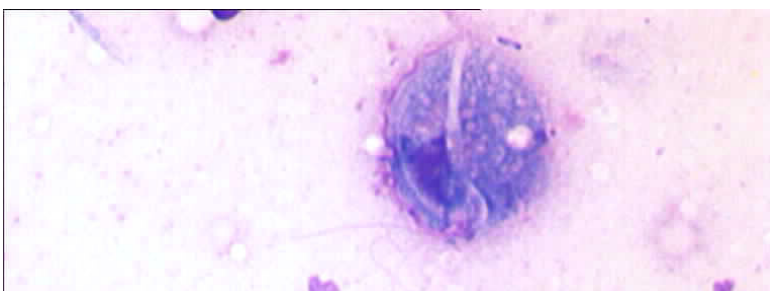

Fig1. Diff-quick-stained faecal smear showing *Tritrichomonas foetus* tachyzoite (courtesy of Daniëlle Gunn-Moore, University of Edinburgh)

Which cats are at risk of *Tritrichomonas foetus* infection?

TF is a particular problem in multi-cat households, notably in pedigree cats (Gookin, *et al* 2004, Gunn-Moore, *et al* 2007), where one or more cats within the group are usually affected. However, non-pedigree cats and cats in rescue shelters can also be affected (Holliday, *et al* 2009, Stockdale,

et al 2009) so TF-associated diarrhoea should not be considered as only a disease of pedigree cats. A high density of cats living together is believed to be the most important risk factor for TF infection due to the likely faeco-oral route of transmission (Gookin, *et al* 2004). TF-associated diarrhoea is most commonly encountered in cats under 1 year of age, but has also been reported in older cats (Holliday, *et al* 2009).

Diagnostic investigation

Definitive diagnosis of TF relies on confirmation of the presence of the protozoal organism in the cat. Other diagnostic investigations may reveal regional lymphadenopathy and corrugation of the large bowel on abdominal ultrasonography. Biopsies of the colon reveal non-specific changes with mild to severe inflammation due to infiltration of lymphocytes and/or plasma cells. Parasites may be seen associated with the mucosa on histopathology.

Diagnosis of *Tritrichomonas foetus*

No test currently exists that can identify 100% of TF-infected cats. If TF is diagnosed, using one of the methods described below, it is very likely that the cat is infected, but a negative result does not completely rule out infection. In these cases the likelihood of diagnosing infection can be increased by using the most sensitive method, repeat testing and testing samples from cats that have signs of diarrhoea and that have not received antibiotics in the 7 days before faecal sampling.

Most of the TF diagnostic methods use faecal samples obtained from the cat for testing. However, an alternative method for collecting samples comprises obtaining a colonic faecal flush from the cat. This involves the use of a soft-rubber catheter that is inserted into the proximal part of the descending colon (~10 cms), with a 10 ml syringe containing warmed sterile saline attached at the end held by the veterinary surgeon. The saline is injected through the catheter and then gently aspirated immediately. The resulting solution can be used for smear examination, culture or polymerase chain reaction (PCR) as outlined below. Further information about this technique can be found via the link entitled 'Fecal sample collection for diagnosis of *T. foetus* infection using the colon flush technique' available at <http://JodyGookin.com>.

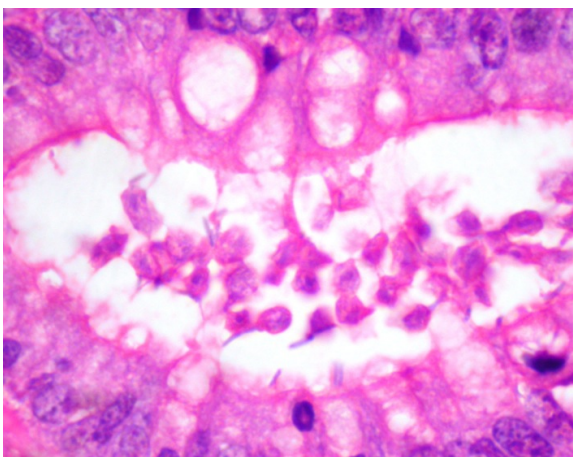


Fig2. Histopathology of a colonic biopsy (H&E staining) showing *Tritrichomonas foetus* tachyzoites in the colonic lumen (courtesy of omparative Pathology Laboratory, University of Bristol)

Faecal smears

Diagnosis of TF initially relied on the observation of small motile TF trophozoites in fresh faecal smears (ideally using faeces <2 hours old) by direct microscopic examination. This is done by examining a mixture of fresh faeces and saline under a cover slip at X200 or X400 magnification. TF trophozoites resemble Giardia trophozoites by microscopy so the examiner must be able to differentiate the two. Live TF shows a forward and progressive, but jerky, movement whereas Giardia move in a more undulating way like a 'falling leaf'. Further information on differentiating these organisms can be found on videos available online via the link entitled 'Videomicroscopy of *T. foetus* and Giardia spp. in feline feces' available at <http://JodyGookin.com>. Although faecal smear examination is cheap, its sensitivity is very low at around 14%.

InPouch™ method

TF infection can now also be diagnosed by culturing the organism using the commercially available Feline InPouchTF™ test kit (BioMed Diagnostics, Oregon, USA). This is associated with improved sensitivity (55%) over faecal smear examinations. It comprises collecting faeces, placing 0.05g into the pouch and incubating at room temperature. The contents are then examined by microscopy every 2 days for the presence of motile TF organisms. The pouch contains a medium that encourages growth of TF together with antibiotics to inhibit the growth of both bacteria and Giardia. However, the InPouch™ method is quite laborious and time-consuming since results can only be considered negative after 12 days. It is of moderate expense.

PCR

More recently faecal PCR has been recommended as the diagnostic assay of choice for TF infection. PCR is advantageous because it is far more sensitive than both direct microscopic examination and culture by the InPouch™ method (Gookin, *et al* 2004), although it is more costly. A number of laboratories worldwide now offer TF PCR so this type of testing is readily accessible to veterinary surgeons. Although faecal PCR has advanced the ease of diagnosis of TF, PCR on faeces can be problematic due to the PCR-inhibitory effect of many substances that are co-purified with the DNA during extraction (Stauffer, *et al* 2008). Although faecal DNA extraction kits exist (Stauffer, *et al* 2008) that can be optimised to minimise the effects of faecal PCR inhibitors, false negative results are still a problem. One solution to this problem is to use a method that assesses the extent of PCR inhibition in the TF PCR assay. This would mean that interpretation of a negative TF PCR is not affected by PCR inhibition. Different methods for assessing PCR inhibition have been used by different labs (Frey, *et al* 2009, Gray, *et al* 2010). One such method that is routinely used by our laboratory is the use of an internal amplification control (IAC). A set amount of IAC is added to all samples before DNA extraction, and subsequent quantitative (Q) PCR measures the amount of IAC present in the sample. This IAC QPCR result tells us if any PCR inhibitory substances are present that could influence the TF PCR result. Laboratories currently offer either conventional (non-quantitative) or QPCRs for the detection of TF in faeces. If a TF QPCR is used, the vet is able to monitor the relative amount of TF present in the faeces (if a standard amount of faeces is used for DNA extraction, as at our laboratory) as this may be useful to monitor response to treatment of TF.

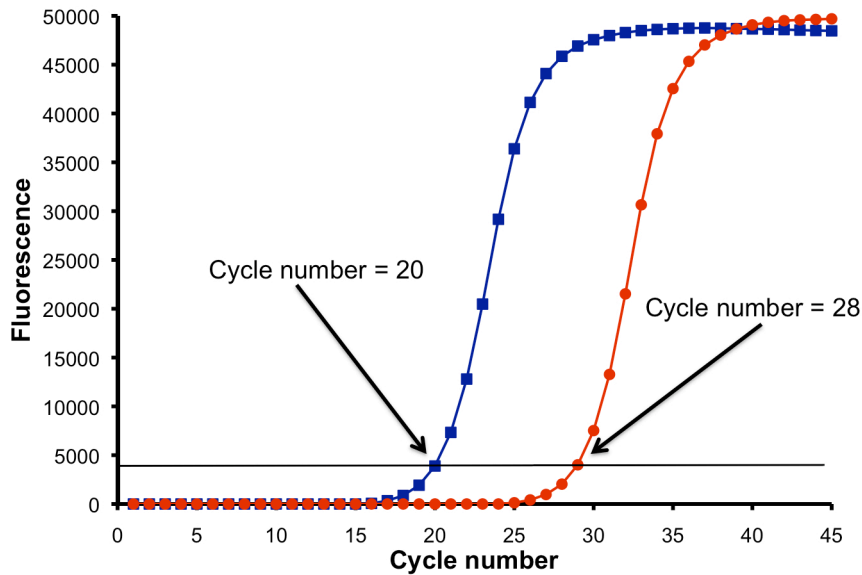


Fig3. The quantitative nature of QPCR allows monitoring of the relative amounts of *Tritrichomonas foetus* DNA present in the faecal sample. The lower cycle number of the blue trace indicates that more *Tritrichomonas foetus* DNA is present in that faecal sample compared to the higher cycle number of the red trace. Results are directly comparable if the same amount of faeces are used for each PCR (Molecular Diagnostic Unit, Langford Veterinary Services, University of Bristol)

Treatment and prognosis of *Tritrichomonas foetus* infection

Provision of a highly digestible diet to affected cats can help control clinical signs and is an important aspect of treatment. Ronidazole, which is related to metronidazole and is used to treat TF in pigeons, has also been used to treat TF in cats. However, this agent is not licensed for use in cats and side effects can occur. Although ronidazole has been effective at resolving clinical signs associated with TF infection, clearance of infection has not always been induced (Holliday, *et al* 2009). A dosage of 30 mg/kg orally once daily for two weeks has been suggested. Neurotoxicosis (lethargy, inappetance, tremors, seizures, ataxia) can occur at higher dosing. Side effects usually resolve once the drug is withdrawn, and this should be done immediately if any signs of toxicity are seen. Ronidazole should not be given to nursing or pregnant queens or kittens less than 12 weeks of age. In some cases it may be that the risks associated with treatment outweigh the inconvenience associated with the cat's diarrhoea and careful consideration, as well as consultation with a feline specialist, is advised before embarking on treatment. Additionally, ronidazole is teratogenic so must be handled with care.

The long-term prognosis for cats with TF infection is generally good, as the diarrhoea will usually resolve spontaneously in untreated cats. However, this often takes many months and cats in which clinical signs (diarrhoea) have resolved may continue to excrete the organism for periods of up to two years.

Further information

Further information about *Tritrichomonas foetus*, including useful videos on diagnostic methods and information on treatment and cat owners, can be found on Dr Jody Gookin's website: <http://JodyGookin.com> or http://www.cvm.ncsu.edu/docs/personnel/gookin_jody.html

Further information about *Tritrichomonas foetus*, including clinical signs and treatment can be found on the Feline Advisory Bureau website: <http://www.fabcats.org/breeders/infosheets/tritrichomonas.html>

Information regarding the QPCRs for *Tritrichomonas foetus* can be found on the Langford Veterinary Services website: http://www.langfordvets.co.uk/lab_pcrnews.htm

References

- Frey, C.F., Schild, M., Hemphill, A., Stunzi, P., Muller, N., Gottstein, B. & Burgener, I.A. (2009) Intestinal *Tritrichomonas foetus* infection in cats in Switzerland detected by in vitro cultivation and PCR. *Parasitol Res*, **104**, 783-788.
- Gookin, J., Stebbins, M., Hunt, E., Bulone, K., Fulton, M., Hochel, R., Talaat, M., Poore, M. & Levy, M. (2004) Prevalence and risk factors for feline *Tritrichomonas foetus* and *Giardia* infection. *Journal of Clinical Microbiology*, **42**, 2707-2710.
- Gookin, J.L., Levy, M.G., Law, J.M., Papich, M.G., Poore, M.F. & Breitschwerdt, E.B. (2001) Experimental infection of cats with *Tritrichomonas foetus*. *Am J Vet Res*, **62**, 1690-1697.
- Gray, S.G., Hunter, S.A., Stone, M.R. & Gookin, J.L. (2010) Assessment of reproductive tract disease in cats at risk for *Tritrichomonas foetus* infection. *Am J Vet Res*, **71**, 76-81.
- Gunn-Moore, D. & Tennant, B. (2007) *Tritrichomonas foetus* diarrhoea in cats. *Vet Rec*, **160**, 850-851.
- Gunn-Moore, D.A., McCann, T.M., Reed, N., Simpson, K.E. & Tennant, B. (2007) Prevalence of *Tritrichomonas foetus* infection in cats with diarrhoea in the UK. *J Feline Med Surg*, **9**, 214-218.
- Holliday, M., Deni, D. & Gunn-Moore, D.A. (2009) *Tritrichomonas foetus* infection in cats with diarrhoea in a rescue colony in Italy. *J Feline Med Surg*, **11**, 131-134.
- Stauffer, S.H., Birkenheuer, A.J., Levy, M.G., Marr, H. & Gookin, J.L. (2008) Evaluation of four DNA extraction methods for the detection of *Tritrichomonas foetus* in feline stool specimens by polymerase chain reaction. *J Vet Diagn Invest*, **20**, 639-641.
- Stockdale, H.D., Givens, M.D., Dykstra, C.C. & Blagburn, B.L. (2009) *Tritrichomonas foetus* infections in surveyed pet cats. *Vet Parasitol*, **160**, 13-17.

Author Details:

**Dr Chris Helps and Dr Séverine Tasker
Molecular Diagnostic Unit and Feline Centre
Langford Veterinary Services
University of Bristol
Langford House
Langford
Bristol
BS40 5DU**



Séverine graduated from the University of Bristol in 1994 and worked for the PDSA before moving to the University of Edinburgh to complete a Feline Advisory Bureau Residency in Feline Medicine. She then moved back to the University of Bristol where she received a PhD investigating feline haemoplasmas. Séverine is currently Senior Lecturer in Small Animal Medicine at Bristol and is involved with the Feline Centre and the Molecular Diagnostic Unit of the Langford

Veterinary Services there. She is a RCVS Specialist in Feline Medicine and European Specialist in Small Animal Internal Medicine. She was awarded the BSAVA Woodrow Award in 2008 for outstanding contributions in the field of small animal veterinary medicine and her main interests are infectious diseases and haematological disorders.



Chris graduated in 1989 with a first in Biochemistry from the University of Bristol. He then went on to complete a Wellcome Trust funded PhD and fellowship there before moving to the Department of Clinical Veterinary Science, Langford, where he is now Senior Research Fellow. Chris has over 18 years' molecular biology experience, has published extensively on the subject and currently heads the Molecular Diagnostic Unit in Langford Veterinary Services, University of Bristol. He is responsible for the research and development of new QPCR diagnostic assays and his areas

of research include the use of novel molecular techniques for the detection and quantification of feline and canine infectious agents and cytokine mRNA and the detection of nucleotide polymorphisms causing feline and canine disease. He was awarded the BSAVA Amoroso Award in 2008 for his major contribution to the development of PCR assays for the diagnosis of feline infectious diseases.

Chris heads the Molecular Diagnostic Unit and is responsible for the research and development of new QPCR diagnostic assays.