



Our Dedicated Staff

- Dr Frances J Barr**, MA VetMB PhD
DVR DipECVIM MRCVS, Senior
Clinical Fellow in Veterinary Imaging
Techniques
- Prof Alistair R. S. Barr**, MA VetMB
PhD DVR DEO Dip ECVS CertSAO
MRCVS, Professor of Veterinary
Surgery
- Dr Kate J Bradley** MA VetMB PhD
DVR DipECVIM MRCVS, Clinical Fel-
low in Diagnostic Imaging
- Neil Burton** BVSc CertSAS MRCVS
Clinical Surgeon in Small Animal
Orthopaedics
- Mr Domingo Casamian Sorrosal**
DVM CertSAM CertVC MRCVS
Clinical Assistant in Cardiorespiratory
Medicine
- Gwen Covey-Crump** BVet Med Cert VA
MRCVS, Clinical Anaesthetist
- Dr Samantha Franklin** BVSc PhD
MRCVS. Senior Lecturer in Equine
Sports Medicine
- Ed Friend** BVetMed CertSAS DipECVIM
MRCVS, Soft Tissue Surgeon
- Prof Edward J Hall** MA VetMB PhD
DipECVIM-CA MRCVS. Head of
Division Professor of Small Animal
Internal Medicine - European Specialist
in Small Animal Internal Medicine
- Ms Andrea M Harvey** BVSc
DSAM(Feline), DipECVIM-C MRCVS.
FAB Clinical Fellow in Feline Medicine.
RCVS Specialist in Feline Medicine &
European Specialist in Small Animal
Internal Medicine
- Miss Angie Hibbert** BVSc CertSAM
DipECVIM-CA MRCVS. Clinical Fellow
in Small Animal Medicine - European
Specialist in Small Animal Internal
Medicine, RCVS Specialist in Feline
Medicine
- Dr Emma Jane Love** BVMS PhD DVA
DipECVAA MRCVS FHEA Clinical Fel-
low in Veterinary Anaesthesia
- Ms Pamela J Murison** BVMS DipEC-
VA DVA MRCVS, Senior Lecturer in
Veterinary Anaesthesia
- Mrs Kate F Murphy** BVSc(Hons)
DSAM DipECVIM-CA MRCVS
PGCert(HE), Senior Clinical Fellow in
Small Animal Emergency and Critical
Care - European Specialist in Small
Animal Internal Medicine

**A recent Case of Septic Pericarditis:
2y, MN, German Short Haired Pointer 'Reggie'**



History: Reggie presented to the Small Animal Medicine Department for investigation of a 3 month history of inappetence, pyrexia, lethargy and weight loss.

Assessment: Reggie was severely depressed and pyrexia. Echocardiography revealed severe pericardial effusion with cardiac tamponade, pericardial thickening, a mass in the caudal lung lobe protruding into the pericardium and a moderate amount of pleural wfluid. No valvular disease was evident. Pericardiocentesis was consistent with a diagnosis of septic pericarditis.

Abdominal ultrasound revealed a right-sided congestive heart failure as a result of cardiac tamponade. After pericardial drainage, Reggie improved clinically, with improved demeanour, good pulse quality and a normal heart rate and blood pressure.

Investigation: Reggie was stabilised overnight in the intensive care unit (ICU) before he was taken to theatre, where a median sternotomy and thoracic exploration was performed. The pericardium was found to be thickened and granulomatous, with similar findings also seen in the consolidated right caudal and middle lung lobes, which were adherent to the pericardium and diaphragm. A subtotal pericardectomy and right middle and right caudal lung lobectomy was performed, along with removal of a portion of the adherent diaphragm. A chest drain was also placed. Histopathology was consistent with pyogranulomatous inflammation and an inhaled foreign body was suspected, although never located. No neoplasia was evident and bacterial culture and sensitivity yielded mixed anaerobes.

Aftercare: Postoperatively, Reggie oozed extensively into his chest from the inflamed tissue, such that his PCV fell from 35% to 12%. His blood type was determined and he received one unit of fresh frozen plasma (FFP) and one unit of packed red blood cells (pRBCs) and required constant ICU monitoring, oxygen supplementation and colloid support. Following this, the ICU team were particularly concerned that he may be developing DIC and/or sepsis: he became systemically very unwell, severely hypoalbuminaemic (13.9g/l, reference range 32-38g/l), was unable to be weaned off oxygen, demonstrated prolonged coagulation times and showed marked lymphopenia and toxic neutrophilia.

24 hours after surgery, Reggie's clinical condition deteriorated so severely that his owners were telephoned to advise that they should visit him and we commenced aggressive fluid therapy (further units of FFP, one unit of whole blood, and high rates of crystalloids and colloids). He demonstrated severe chest pain consistent with pleuritis and after assessment by the anaesthesia team, he was started on a constant rate infusion of ketamine. Constant monitoring of his basic parameters was continued, including assessment of central venous pressure, arterial blood pressure, blood oxygenation (SpO2), ECG and urine output every 5 minutes. He developed moderate generalised oedema, which was likely due to the hypoalbuminaemia. Fortunately, with intensive nursing, Reggie slowly started to improve over the next 48 hours.

Home care and follow up: Two weeks after admission and following hours of driving for his dedicated owners, Reggie was eventually discharged from the hospital in time for Easter. His recovery would not have been possible without 24-hour a day care from nurses and clinicians across all the departments of imaging, ICU, medicine, cardiology, surgery, anaesthesia and pathology. Additional thanks should also go to Chester the Golden Retriever, who generously donated the unit of whole blood which Reggie so desperately needed.

Kelly Bowlit. Resident in Small Animal Surgery



Our Dedicated Staff

Peri Lau-Gillard, DVM CertVD MRCVS. Clinical Associate in Dermatology

Natalie Perrins BVetMed CertVD DipECVD, Veterinary Dermatologist

Dr Joanna Murrell, BVSc PhD CertVA DipECVA MRCVS, Senior Lecturer in Veterinary Anaesthesia

Dr Kostas Papasouliotis DVM PhD DipRCPath DipECVCP MRCVS Senior Lecturer in Veterinary Clinical Pathology/Academic in charge of Diagnostic Labs

Dr Séverine Tasker BSc BVSc(Hons) PhD DSAM DipECVIM-CA PGCert(HE) MRCVS, Senior Lecturer in Small Animal Medicine - RCVS Specialist in Feline Medicine & European Specialist in Small Animal Internal Medicine

Ms Kathleen Tennant BVetMed CertSAM CertVC FRCPath MRCVS Clinical Fellow in Veterinary Clinical Pathology

Mr Henry Tremaine BVetMed MPhil Cert ES Dip ECVS MRCVS. Senior Teaching Fellow in Equine Surgery RCVS Specialist in Equine Surgery

Adrian Wallace BVSc(Hons) MACVSc(SAS) Dip ECVS MRCVS Orthopaedic Surgeon

Mrs Sheena M Warman, BSc BVMS DSAM DipECVIM-CA PGCert(HE) MRCVS, Clinical Fellow in Small Animal Medicine - European Specialist in Small Animal Internal Medicine

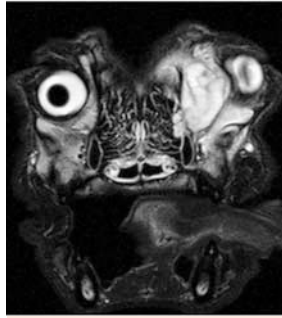
Should Loyalty be Rewarded?

We believe it should! We provide 10% of case value back to you as flexible CPD rewards. For more information or to register, visit our website: www.langfordvets.co.uk or call Kat Hall: 07876 342060

24 hour Blood Glucose Monitoring

The Medicine Service is now able to offer **24 hour Blood Glucose Monitoring for cats and dogs**. This is particularly useful for poorly controlled or stressed out diabetics, who can relax in our hospital facilities while our new monitor tracks their blood glucose levels throughout the day and night, avoiding frequent blood sampling. If you have a case you think would benefit from this service please call our small animal reception to be put in touch with our medicine clinicians.

Spotlight on MRI – now available for outpatients!



Retrobulbar mass identified on a canine patient

Our clinicians prefer high resolution machines (1.5 Tesla) as the higher field strength means we can acquire detailed images of a very high quality. Thin slices with excellent resolution can be acquired, allowing even subtle lesions to be identified. This gives our diploma holders Frances Barr and Kate Bradley far more information when imaging neurological cases, enabling them to confirm or rule out small disc lesions or subtle change present in diseases such as GME with confidence. The greater size of the mobile machine also allows us to offer the service to giant breed dogs.

Imaging and interpretation costs £1000-£1300 (inc. VAT) depending on the number of areas to be scanned. **If you would like MRI only, rather than full referral, please contact our Small Animal Hospital reception staff to book: 0117 9289420/ 9447**

Welcome back Domingo!



Langford Veterinary Services welcome Domingo Casamian DVM CertSAM CertVC MRCVS to work in our Cardiorespiratory Service.

After graduating from the University of Zaragoza Domingo carried out an internship at the Animal Medical Centre in Manchester. He then worked at Ashfield House Veterinary Hospital in Nottingham and Rowe Referrals in Bristol combining these positions with long externships at the Cardiorespiratory Centre in Kenilworth. A residency with us, in small animal medicine followed in 2009. Domingo obtained the RCVS Certificate in Small Animal Medicine in 2004 and the RCVS Certificate in Veterinary Cardiology in 2006. He is working towards the ECVIM diploma (Internal medicine) and the RCVS diploma (Cardiology).

Domingo will be visiting practices to provide informal lunchtime CPD. If you would be interested in meeting him please contact Kat Hall: 07876 342060 / k.hall@bristol.ac.uk.

We accept all types of cardiorespiratory referrals in dogs and cats and we will be happy to discuss any case with you. For advice or referral please call our Small Animal Hospital reception on 0117 9289420 / 9447 or e-mail: sah@langfordvets.co.uk

Natalie Perrins joins our team

We are pleased to announce the appointment of Natalie Perrins BVetMed CertVD DipECVD to join our team of dermatologists.

Natalie graduated from the RVC in 2001. She then worked in small animal practice for 2 years before returning to the RVC to undertake a 3 year residency in Veterinary Dermatology. Natalie attained her RCVS Certificate in Veterinary Dermatology in 2006. Since completing her residency in 2006 Natalie has been working at The Animal Health Trust, Newmarket and was awarded her European Diploma in Veterinary Dermatology in 2009. She is interested in all types of dermatological cases with emphasis on allergic skin and ear diseases in dogs and cats. Natalie will be visiting practices to provide informal lunchtime CPD. If you would be interested in meeting her please contact Kat Hall: 07876 342060 / k.hall@bristol.ac.uk.

Natalie is very happy to provide telephone advice should you wish to discuss a case; please call the Small Animal Hospital reception on 0117 9289420 / 9447.



Congratulations...



Congratulations to Angie Hibbert BVSc CertSAM DipECVIM-CA MRCVS who has been recognised by the RCVS as a Specialist in Feline Medicine. Previously only 8 such clinicians were recognised by the RCVS! Angie completes our feline team of four recognised feline

Specialists – the largest in the UK.

Congratulations to Neil Burton BVSc CertSAS MRCVS our Clinical Surgeon in Small Animal Orthopaedics. Neil was recently awarded the Leslie Vaughan prize for the best orthopaedic abstract presented at BSAVA.

